

PATIENT SPOTLIGHT

Hyperparathyroidism During Pregnancy

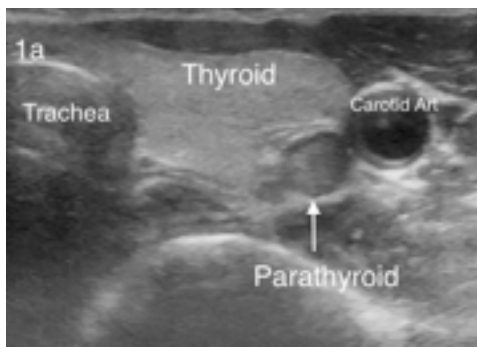


Fig 1a. Axial ultrasound of the neck showing a parathyroid adenoma.

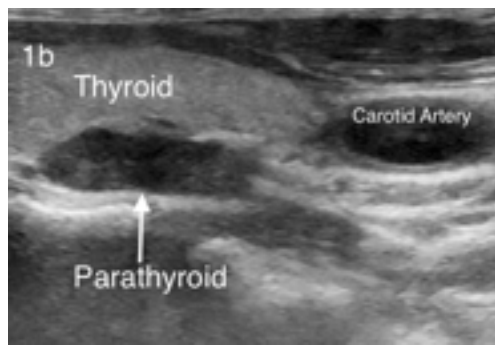


Fig 1b. Sagittal images of the ultrasound of the neck.

A 31 year old pregnant woman with abnormal lab values on routine testing.

CLINICAL SIGNS AND MANAGEMENT

The patient was a 31-year-old female who was 18 weeks pregnant. Routine lab work showed a calcium level of 12.9 and a subsequent parathyroid level of 191. She was placed on a low calcium diet and her calcium level dropped to 11.8. Her pregnancy was uncomplicated, and the fetus was growing appropriately. She denied depression, or bone and joint pain but had fatigue she thought was related to her pregnancy. For her workup, because of concerns about radiation exposure to the fetus, sestamibi parathyroid scanning or 4D CT scan could not be used. Ultrasound showed an enlarged left inferior parathyroid adenoma (Figure 1a axial, 1b sagittal). The Maternal-Fetal OB/GYN team recommended local anesthesia with IV sedation and during the entire surgical procedure, the Maternal-Fetal OB/GYN team monitored the fetus and were ready in case an emergency cesarean section was needed. The parathyroid surgery was performed at 24 weeks through a 2.5 cm incision in the midline low in the neck. We started the exploration on the left side, and within 10 minutes, an enlarged left inferior parathyroid adenoma was identified and removed (Figure 2). The abnormal gland weighed 730 mg. Two weeks after surgery, the patient's calcium level was 9.1 and parathyroid level was 39. Both mother and baby did well.



ENT and Allergy
Associates, LLP

This patient was
referred by a tri-state
ENTA physician.

Our shared EHR
facilitates a seamless
referral process and
transfer of medical
records with the push
of a button.

To refer a patient:

Call us direct at
Physician Access Services
(212)241-4983

Thank you for your
referrals.

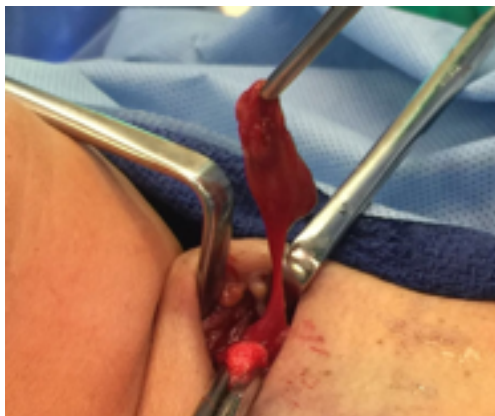

Fig 2. A large left inferior parathyroid adenoma was identified.

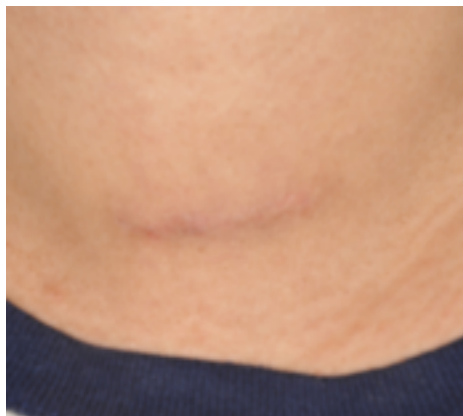

Fig 3. A well healed incision post-op

CLINICAL REVIEW

Due to the low incidence of hyperparathyroidism during pregnancy, the full deleterious effects are unknown and clear guidelines for treatment are not available. Because of this lack of guidelines, there is a reluctance to operate on patients while pregnant, particularly patients with relatively mild levels of hypercalcemia. However, more and more information is accumulating that suggests that hyperparathyroidism can have severe effects on both the mother and the fetus. Reports in the literature show up to a 67% maternal complication rate with the most common being hyperemesis, nephrolithiasis, preeclampsia, muscle weakness, pancreatitis, arrhythmias, bone disease, mental status changes and hypercalcemic crisis. Hyperparathyroidism in the mother can have significant effects on the fetus with reports of growth retardation, preterm delivery, intrauterine demise, hypoparathyroidism and hypocalcemic tetany. Reports show that up to 50% of babies born to untreated hyperparathyroid mothers will suffer from tetany, and some of these babies will have permanent hypoparathyroidism.

One of the larger studies in the literature with 32 women showed a 6-fold increase in the rate of pregnancy loss in the second trimester in patients with hyperparathyroidism. These authors suggested that even with relatively mild levels of elevated calcium, the rate of pregnancy loss is significantly elevated and they advocated surgical intervention during pregnancy to prevent these losses. Due to concerns about the complications related to hyperparathyroidism, we performed surgical exploration during her pregnancy. She had a single adenoma as a cause of her symptoms and was cured when it was removed. The remainder of her pregnancy was uncomplicated and her baby was delivered full-term and healthy.



By Mike Yao MD

Associate Professor
Department of Otolaryngology
Head And Neck Surgery
The Mount Sinai Hospital

MOUNT SINAI OTOLARYNGOLGY

Eric M. Genden, MD
Chairman
Head and Neck Cancer

William Lawson, MD, DDS
Vice-Chairman
Rhinology and Facial Plastics

Bartolomeo V. Castellano, MD
General Otolaryngology

Mark Courey, MD
Director, Laryngology

Satish Govindaraj, MD
Director, Endoscopic Skull
Base Surgery

Alfred Iloreta, MD
Rhinology and Skull
Base Surgery

Fred Y. Lin, MD
Director, Sleep Surgery

Brett A. Miles, MD, DDS
Head and Neck Cancer

Joshua D. Rosenberg, MD
Facial Plastics,
Head and Neck Cancer

Marita S. Teng, MD
Head and Neck Cancer

Benjamin Tweel, MD
General Otolaryngology

Mike Yao, MD
Head and Neck Cancer

Manhattan:

Faculty Practice Associates
5 East 98th Street, 8th Floor
New York, NY 10029

Faculty Practice Associates
234 East 85th Street
New York, NY 10029

Center for Science and Medicine
10 East 102nd St, 3rd Floor
New York, NY 10029

Staten Island:

2052 Richmond Road, Suite C
Staten Island, NY 10306